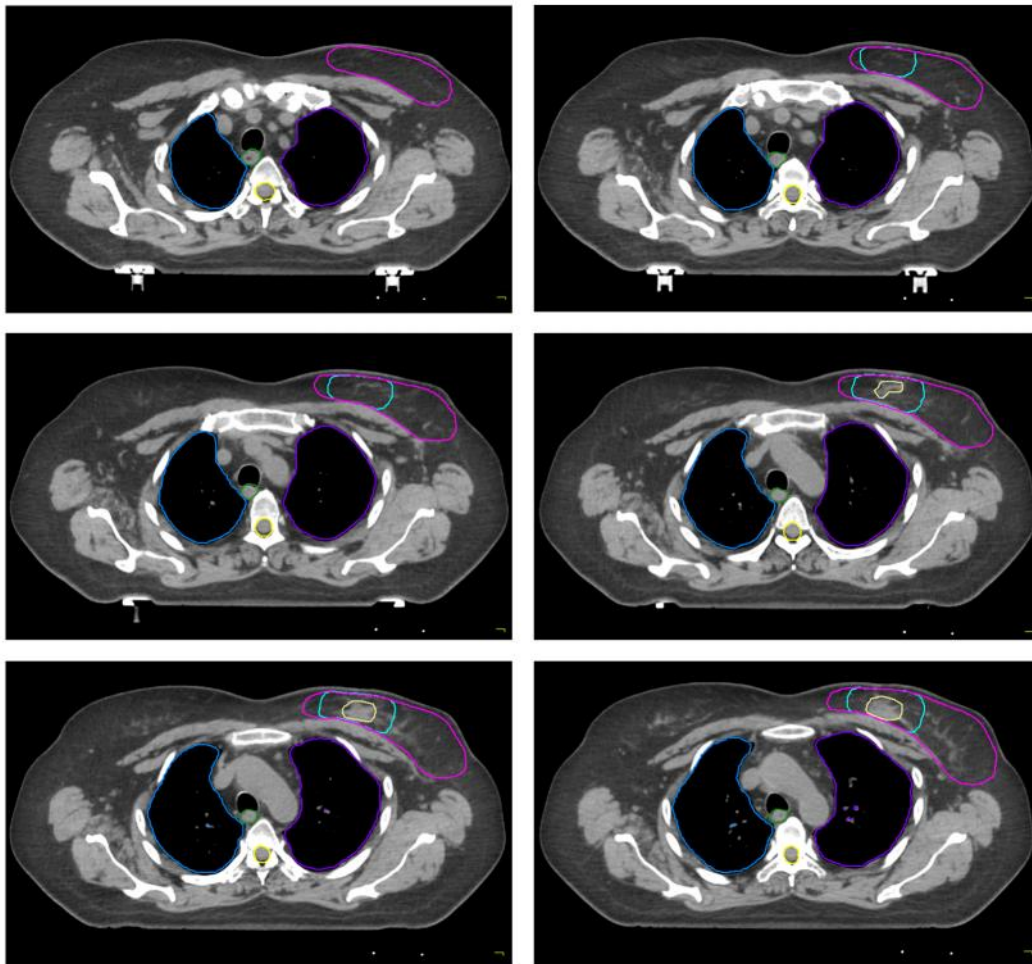









ATLANTE DI CONTORNAZIONE

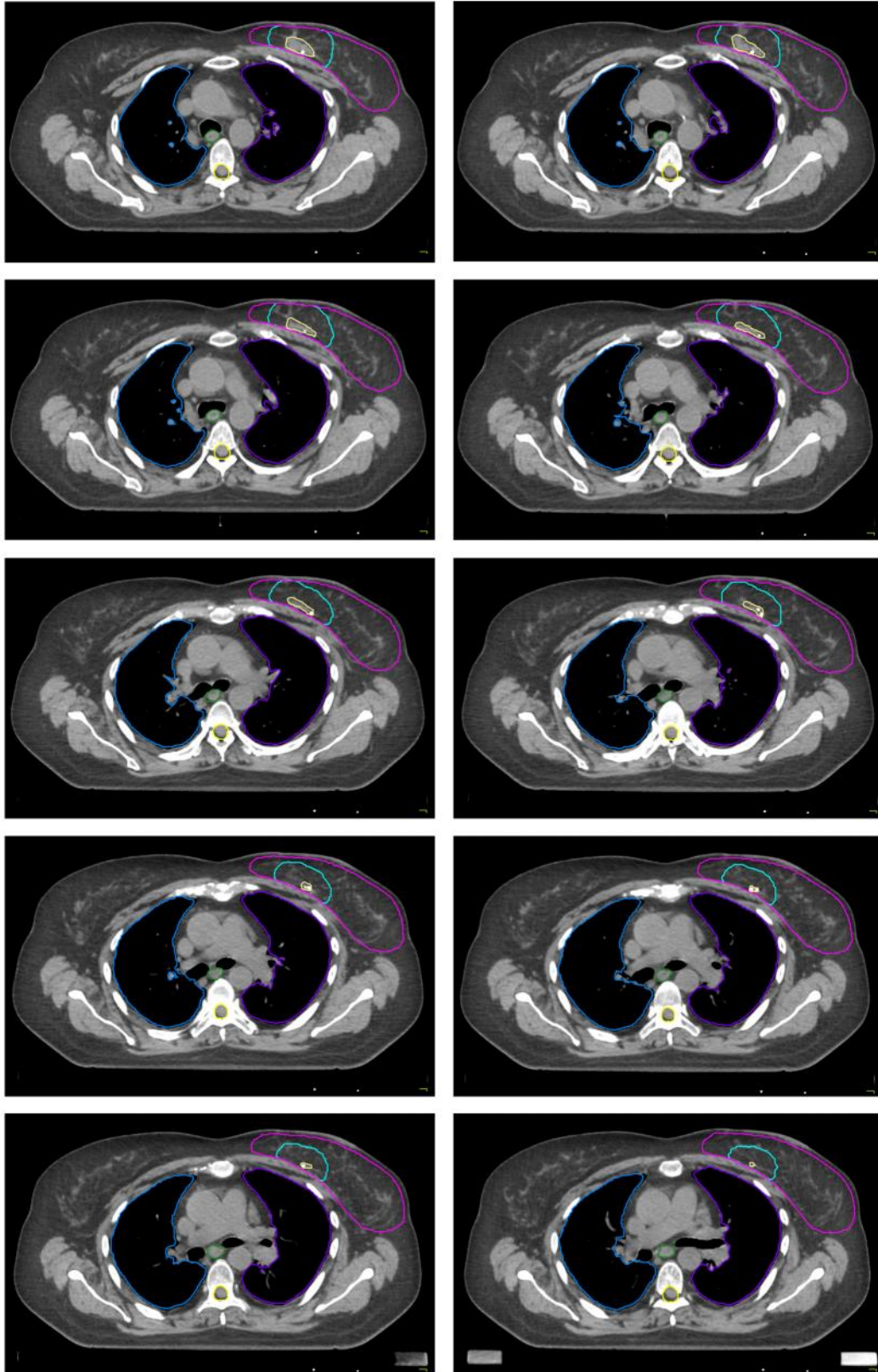
Caso clinico 1

- Paziente di 55 anni, KPS 100%;
- Assenza di familiarità per neoplasia mammaria e comorbidità di rilievo;
- Esami di stadiazione negativi;
- Intervento chirurgico di quadrantectomia supero-interna della mammella sinistra ed asportazione di 3 linfonodi sentinella ascellari omolaterali;
- Diagnosi istologica: CLI G3 di 3,5 cm di diametro; focolai di carcinoma lobulare in situ variante classica (LIN 1-2); immagini di invasione neoplastica peritumorale. Margini indenni. Tre linfonodi sentinella indenni da metastasi. Caratterizzazione biopatologica: RE: 80%; PgR: 70%; Ki-67: 30%; Hercept test negativo (0). Stadiazione TNM: Stadio IIA pT2 pN0 (sn) M0







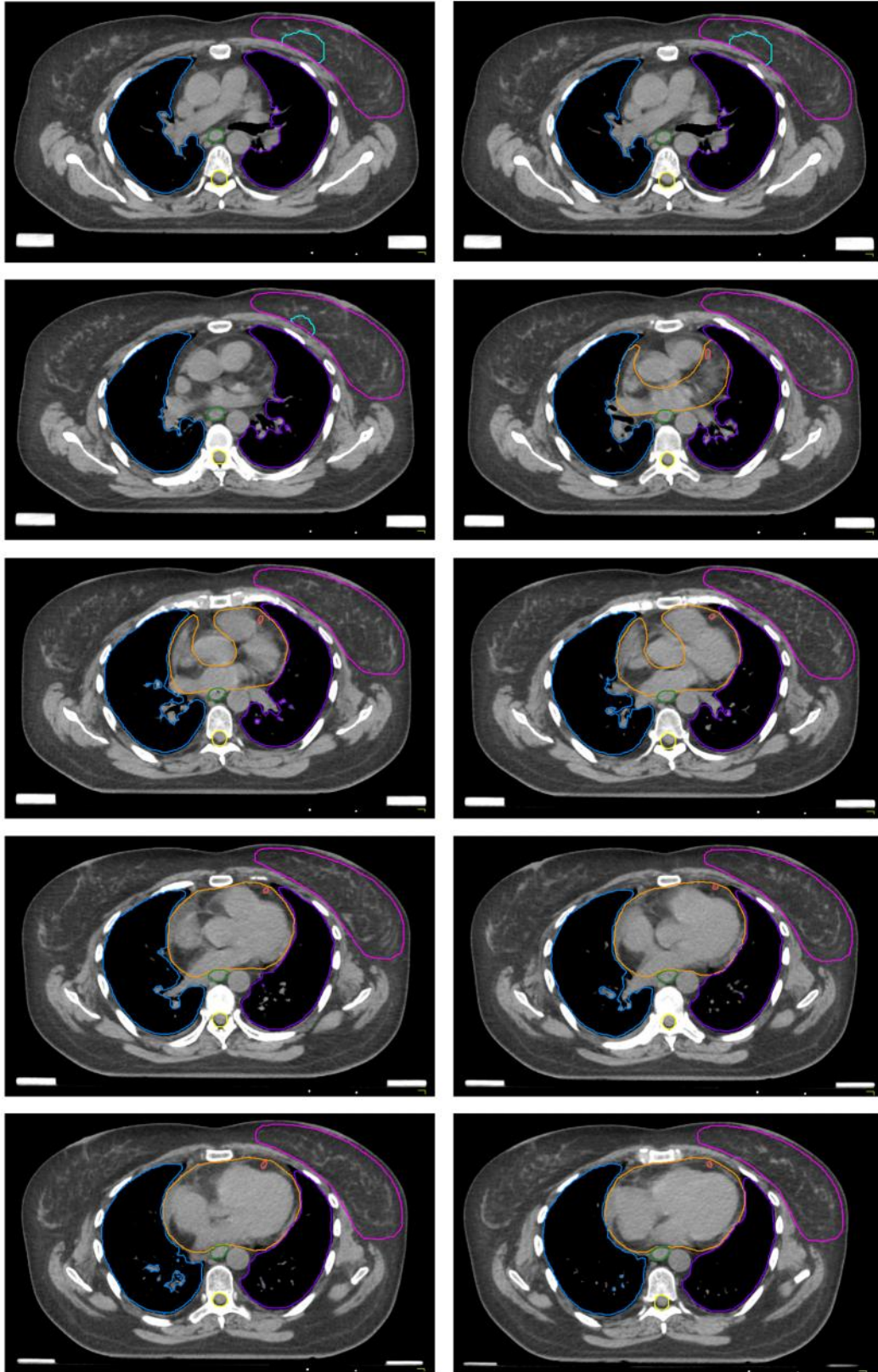
Legenda

	Polmone destro		Polmone sinistro		Esofago
	Midollo spinale		Cuore		LAD
	CTV mammella		Clips + sieroma		CTV boost






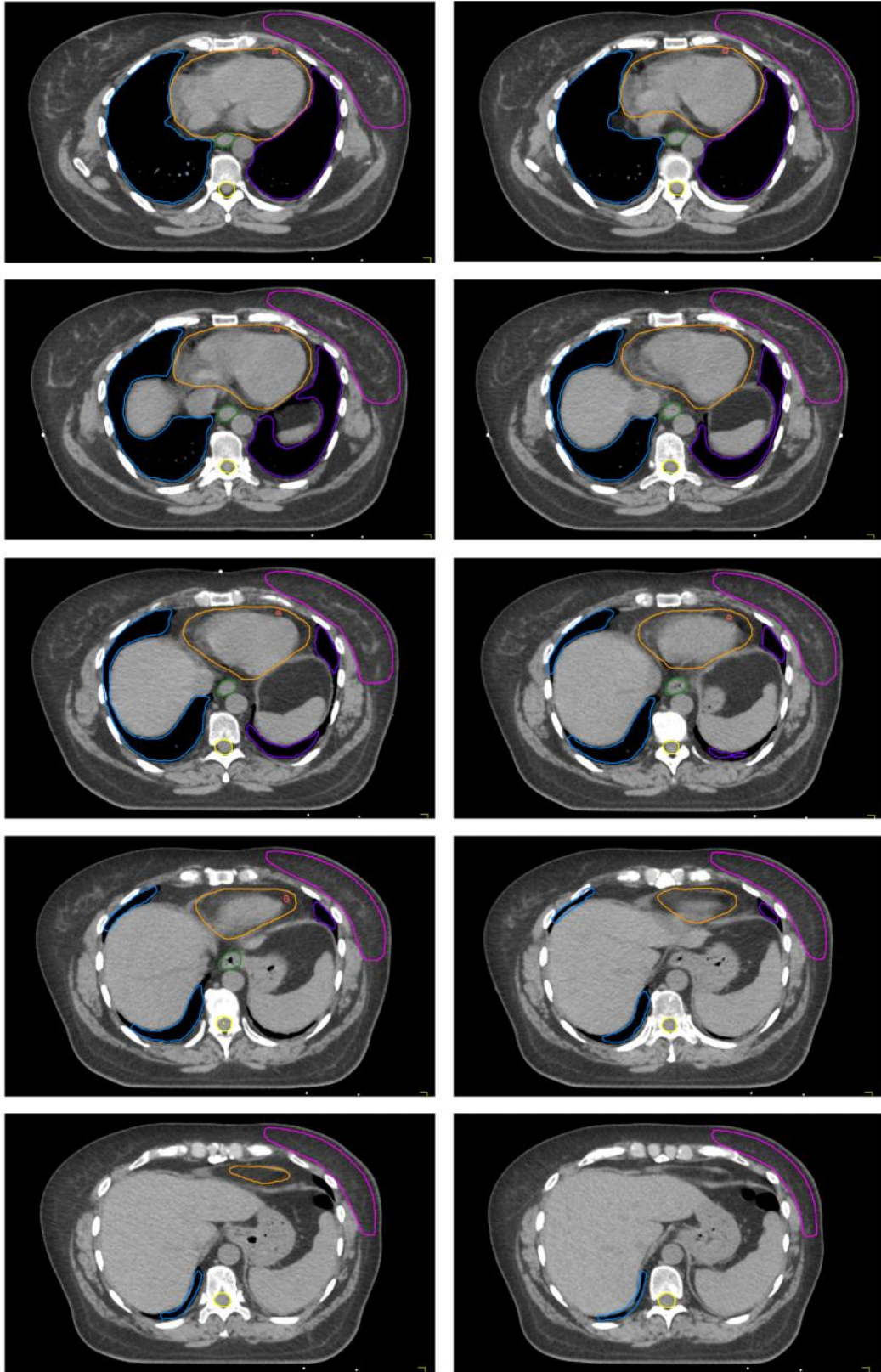
Legenda

	Polmone destro		Polmone sinistro		Esofago
	Midollo spinale		Cuore		LAD
	CTV mammella		Clips + sieroma		CTV boost












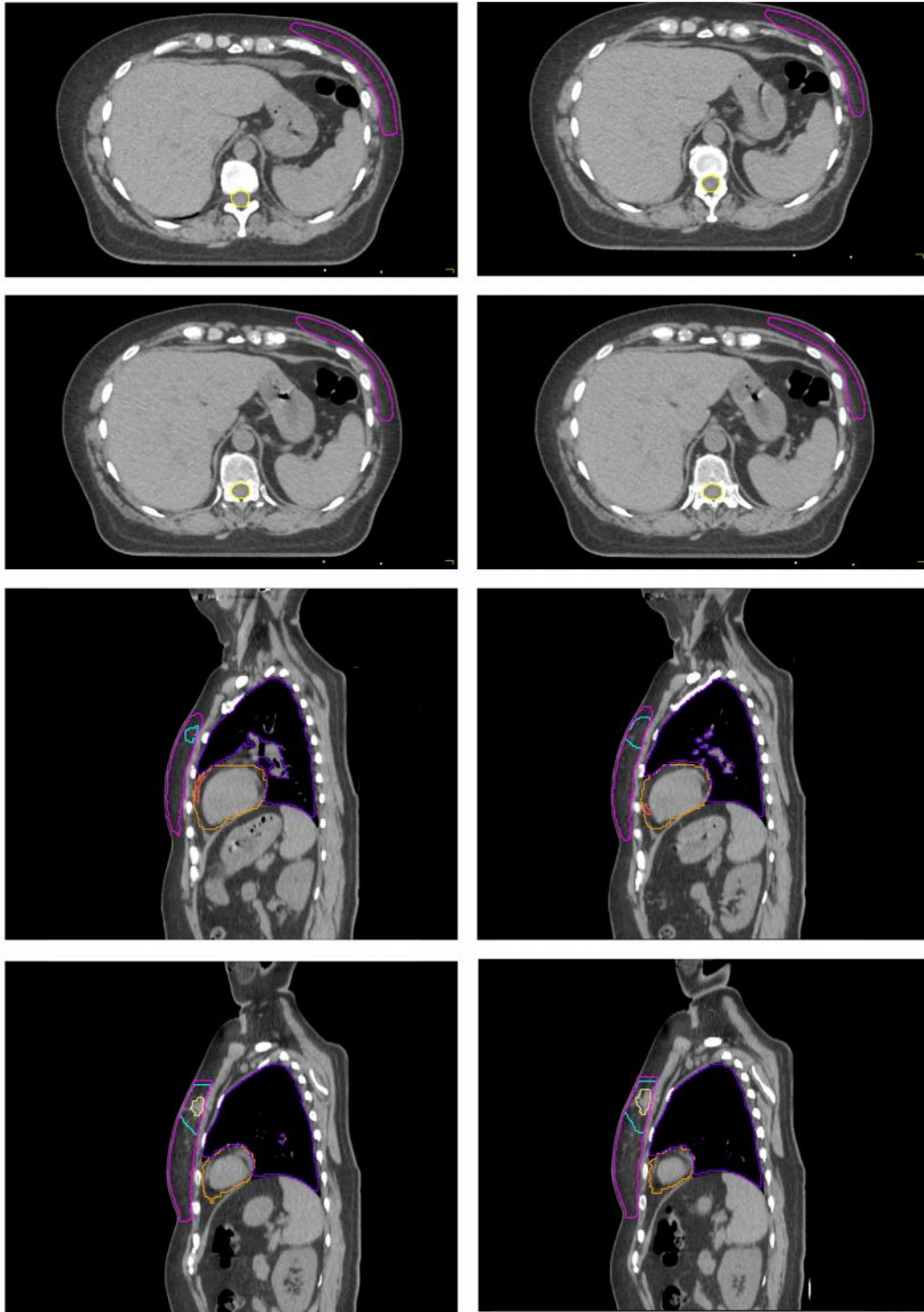
Legenda

- | | | | | | |
|---|-----------------|---|------------------|---|-----------|
|  | Polmone destro |  | Polmone sinistro |  | Esofago |
|  | Midollo spinale |  | Cuore |  | LAD |
|  | CTV mammella |  | Clips + sieroma |  | CTV boost |






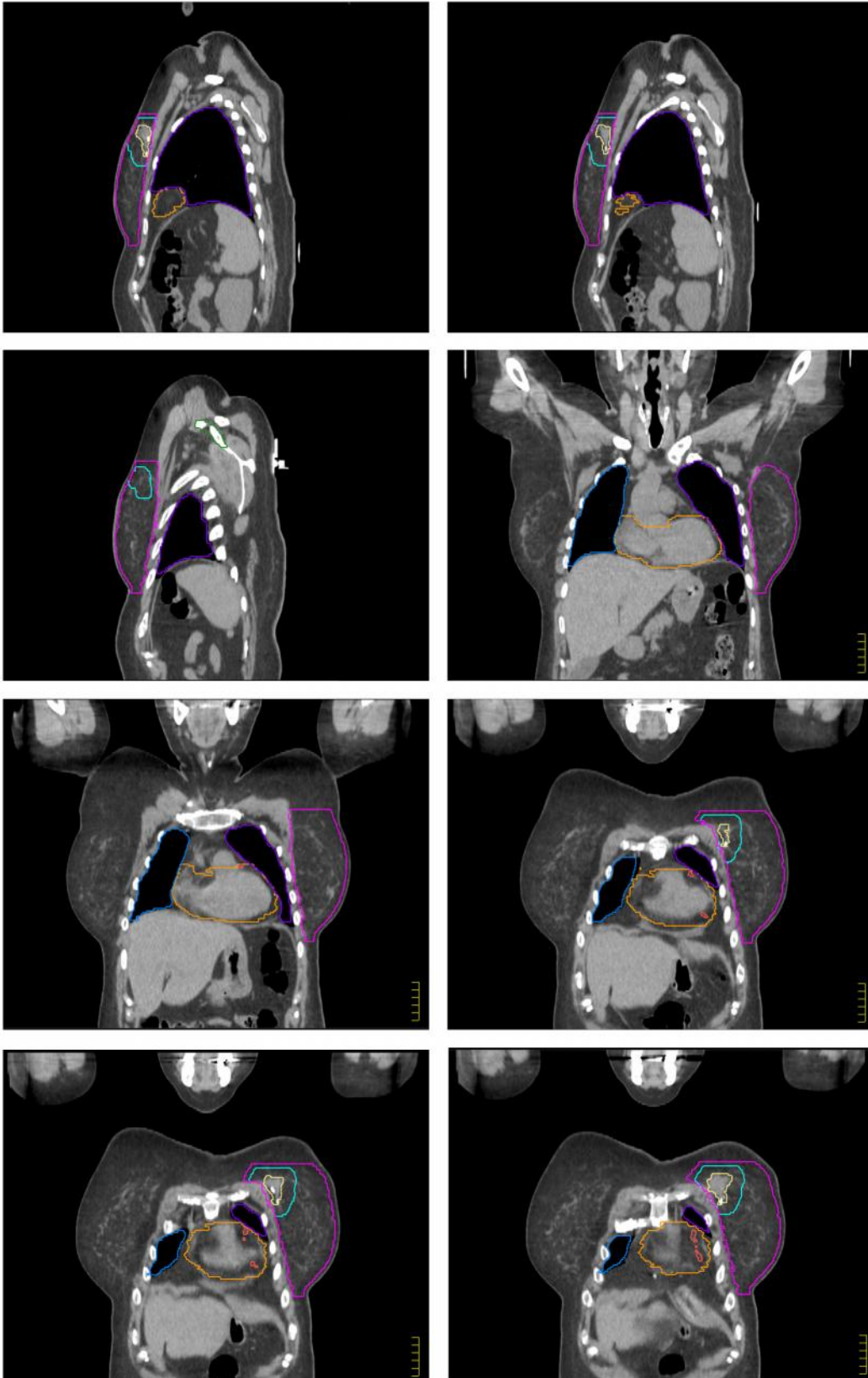
Legenda

	Polmone destro		Polmone sinistro		Esofago
	Midollo spinale		Cuore		LAD
	CTV mammella		Clips + sieroma		CTV boost




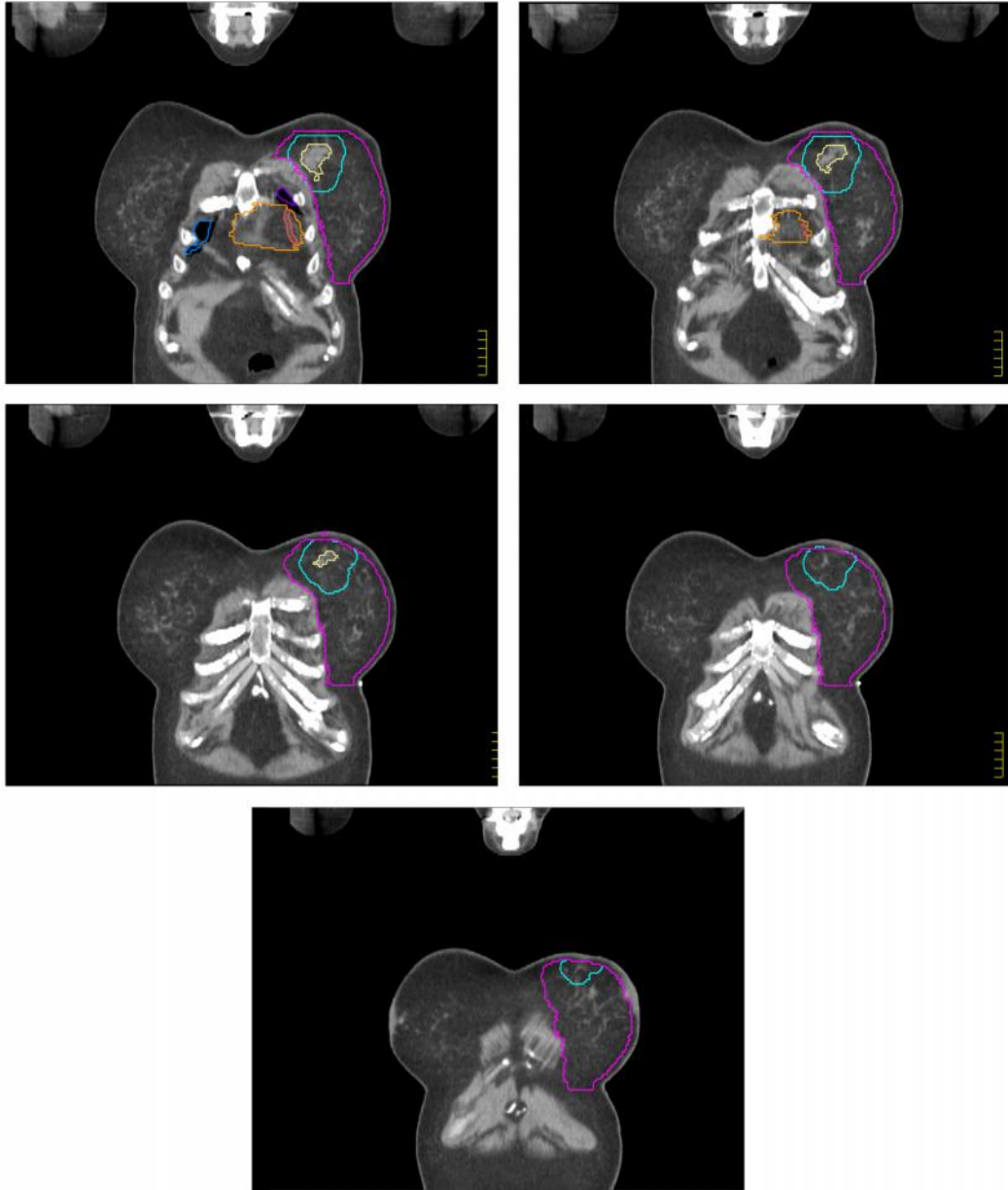
Legenda

	Polmone destro		Polmone sinistro		Esofago
	Midollo spinale		Cuore		LAD
	CTV mammella		Clips + sieroma		CTV boost












Legenda

	Polmone destro		Polmone sinistro		Esofago
	Midollo spinale		Cuore		LAD
	CTV mammella		Clips + sieroma		CTV boost



Legenda

	Polmone destro		Polmone sinistro		Esofago
	Midollo spinale		Cuore		LAD
	CTV mammella		Clips + sieroma		CTV boost